

Introduction

- Episodic memory relies on a distributed network of regions in the brain, including cortical regions in the frontal and temporal cortices (Dickerson & Eichenbaum, 2009).
- Along with memory, research shows that cortical regions undergo great development in early childhood (Sur & Leamey, 2001)
- Previous studies have shown that neural pruning and myelination takes place during childhood development.
- However, little is known about how changes in cortical regions might relate to memory development during this time period.
- **The present study aims to investigate associations between cortical thickness and performance on an episodic memory task**


Methods

Participants

- 200 children aged 4- to 8-years-old (M = 1.50, SD = 0.50, 100 females)
- Out of 200 children, 6 children did not undergo scanning and 1 child was identified as an outlier (3 SD from the mean).

Memory Assessment

- Children completed an Ordered Recall Task (Weintraub et al., 2008)
- 9 pictures with a common theme were presented one-by-one
- The pictures then were shuffled and re-presented
- Children were asked to reconstruct the sequence
- Variables used: All Adjacent Pairs

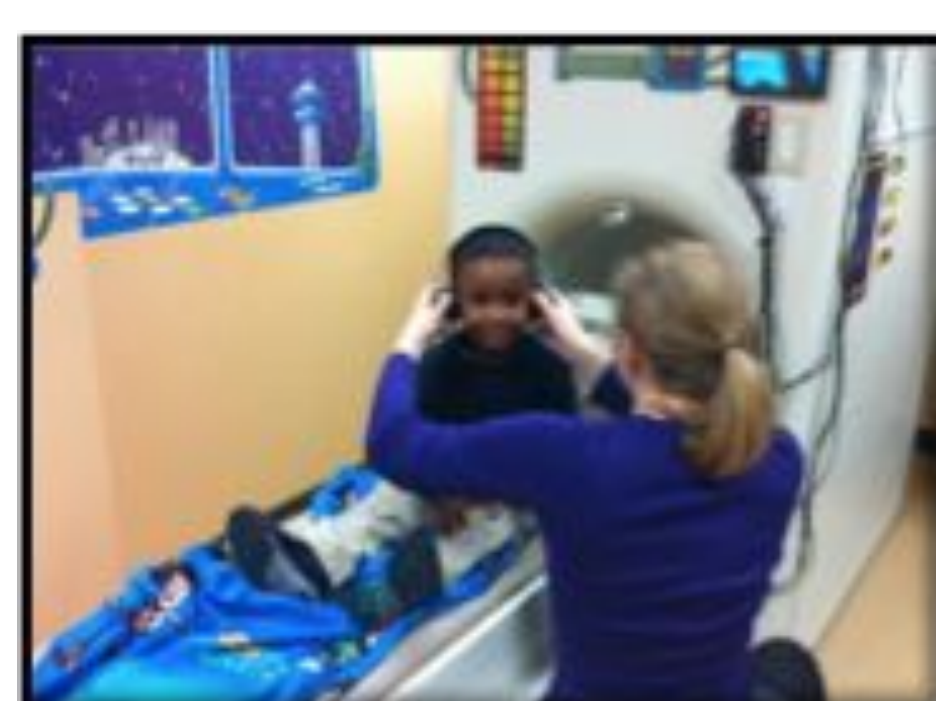
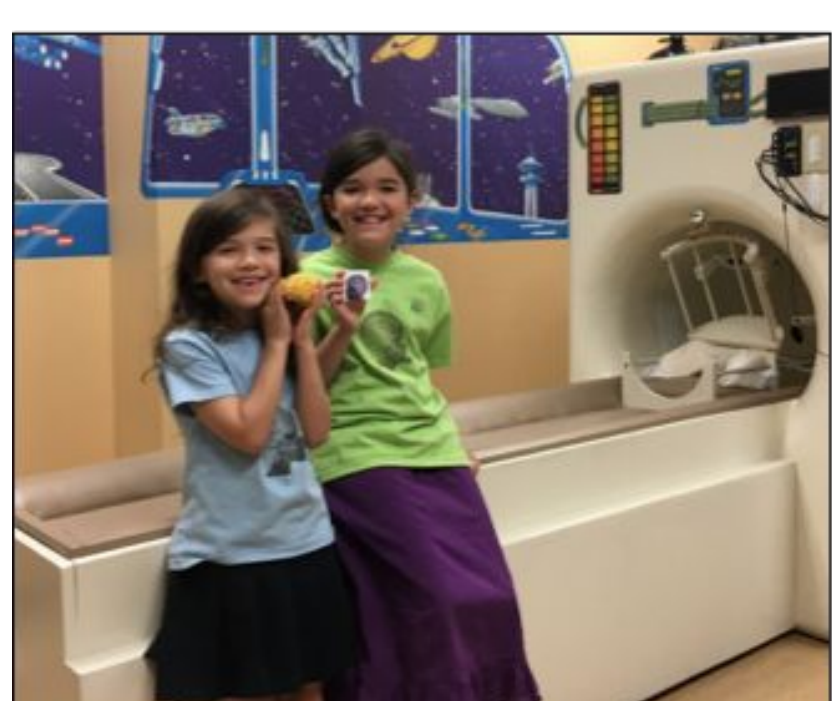
IQ Assessment

- Children were administered age-appropriate IQ tests (WISC and WPPSI).

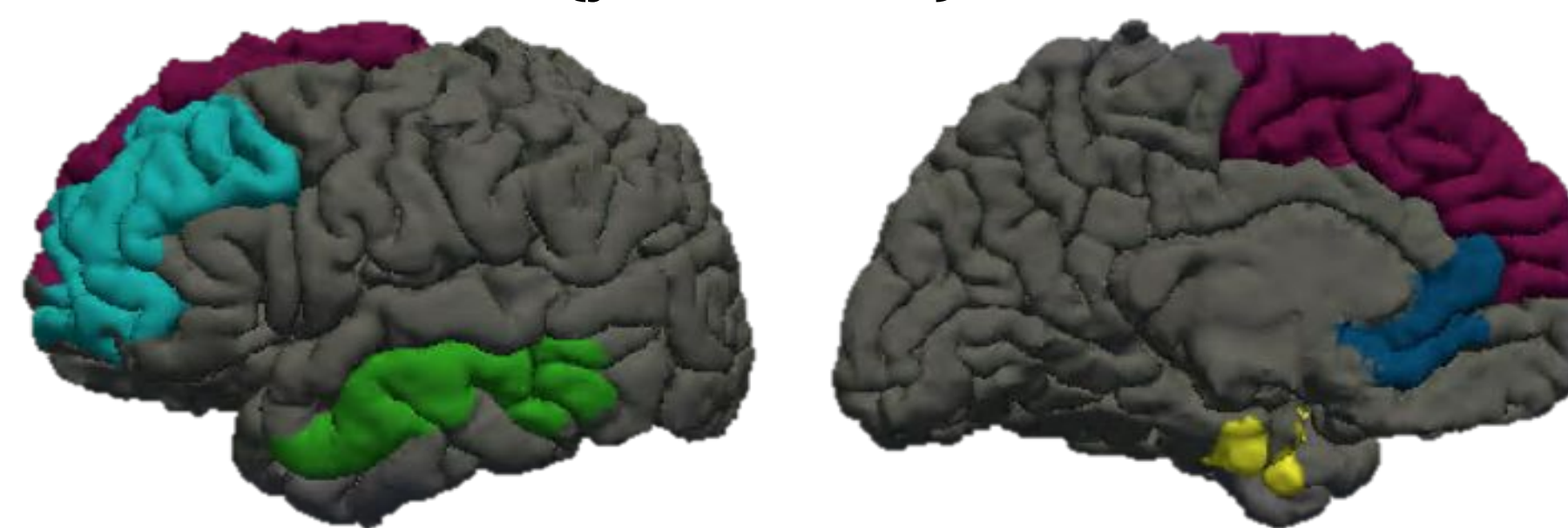
MRI Acquisition

- High resolution (1mm³) T1-weighted anatomical brain images were obtained from a Siemens 3T scanner with a 32-channel coil
- Freesurfer v5.1 was used to calculate cortical thickness (Fischl, 2012).
- Boundary lines between CSF, gray matter, and white matter were reviewed for accuracy & manual edits were completed when necessary.



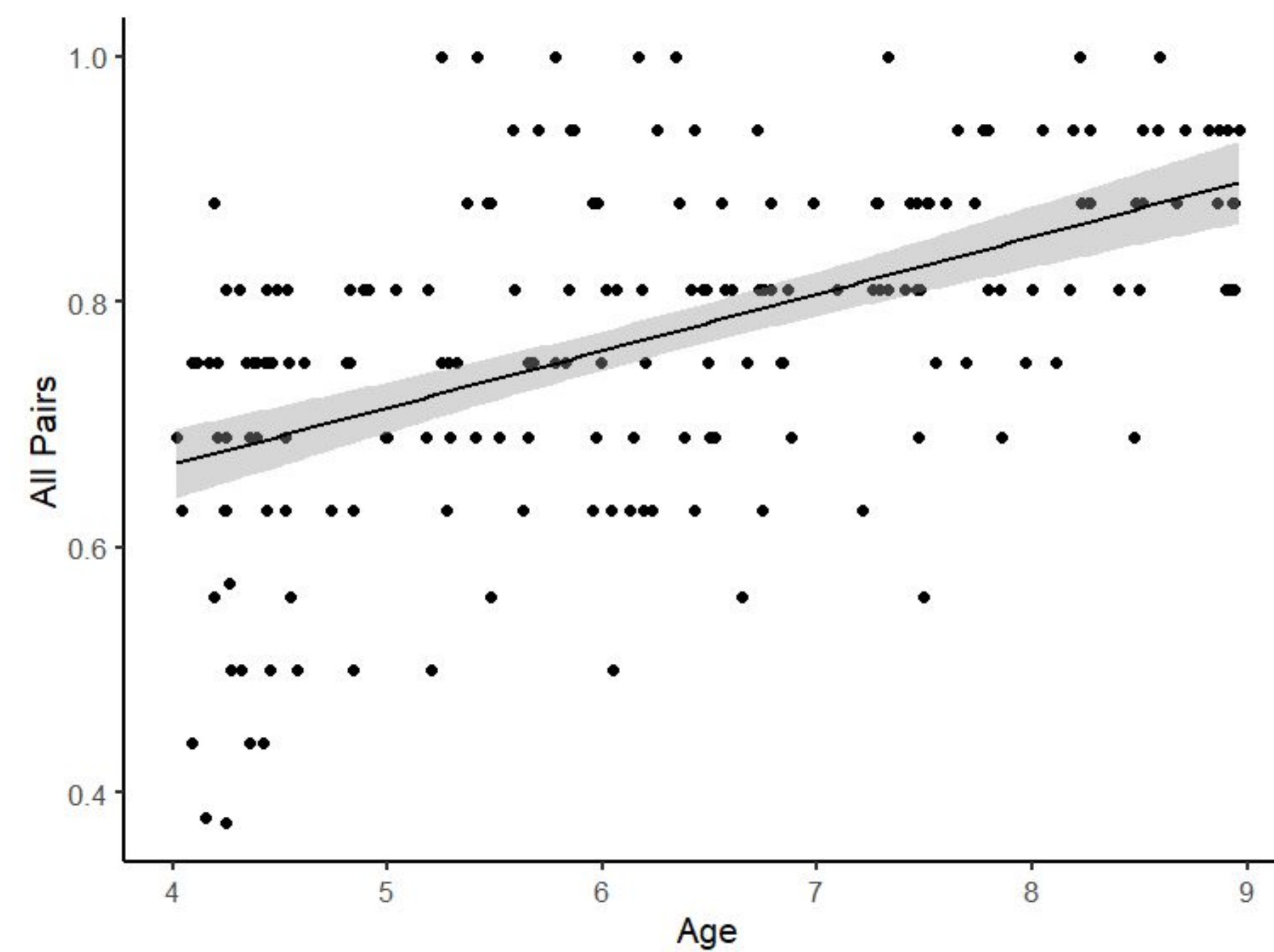
Methods: Regions of Interest

- Left and right hemispheres of each region of interest (ROI) were averaged to create bilateral ROIs. The following ROIs were examined:
 - Superior frontal cortex (purple, SFC)
 - Middle frontal cortex (light blue, MFC)
 - Anterior cingulate cortex (blue, ACC)
 - Medial temporal cortex (green, MTC)
 - Entorhinal cortex (yellow, EC)



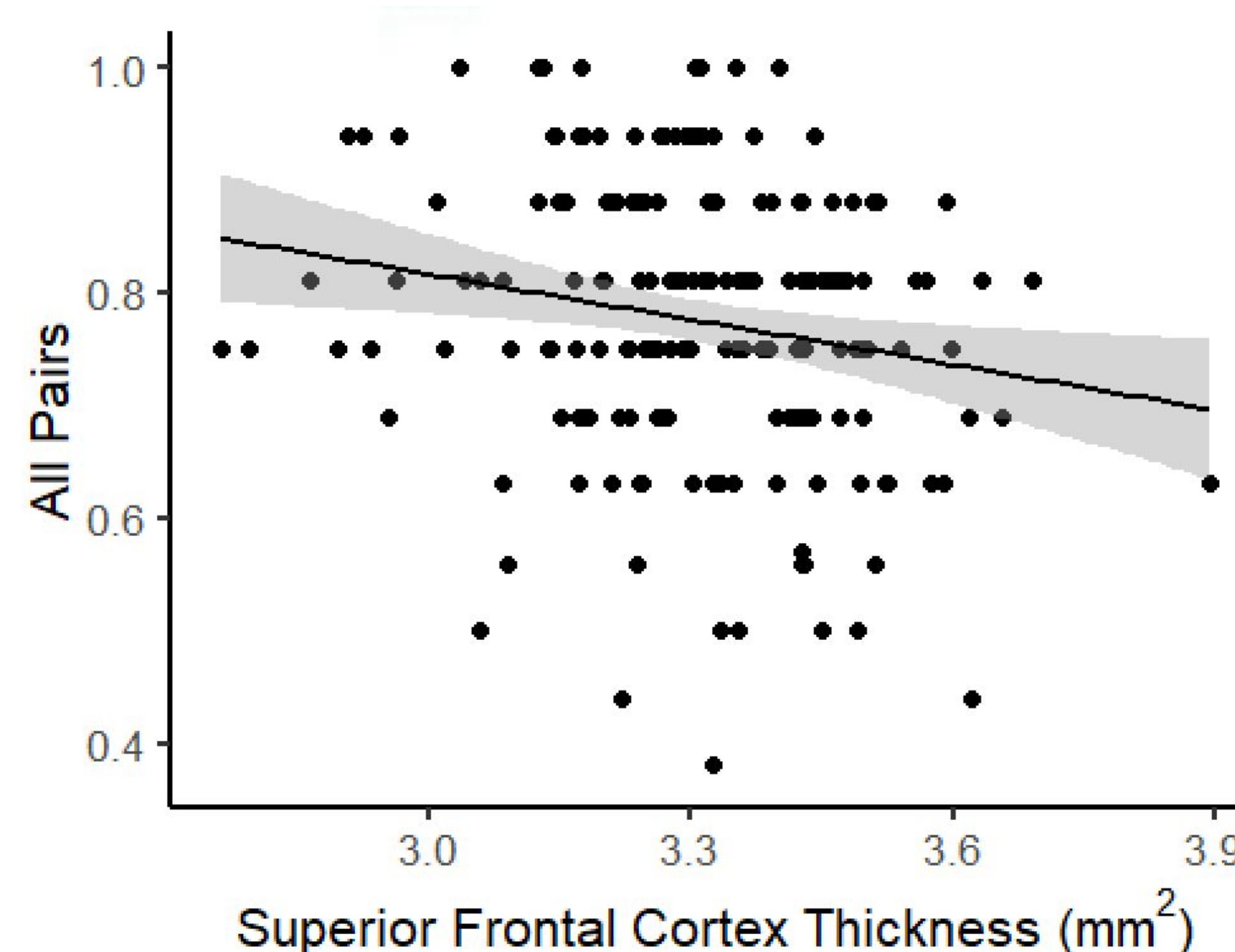
Results: Age and Memory Associations

- Bivariate correlations showed significant positive associations between Age and memory performance ($r = .53$, $p < .001$).



Results: Cortical Thickness and Memory Associations

- Associations between each ROI and memory were assessed via bivariate correlations.
 - SFC ($r = -0.15$, $p < .05$) and ACC ($r = -.23$, $p < .001$) showed negative associations with memory.



Results: Regression

- Multiple regressions revealed that SFC, but not ACC, remained a significant predictor of memory after controlling for age, gender, and IQ.

Table 1. Results from regression predicting memory from superior frontal thickness.

	Standardized B	SE	p
Age	0.48	7.425	<0.001
Gender (M=1)	0.79	1.224	0.223
IQ	0.98	1.534	0.127
Superior Frontal	-0.148	-2.303	0.022

Discussion

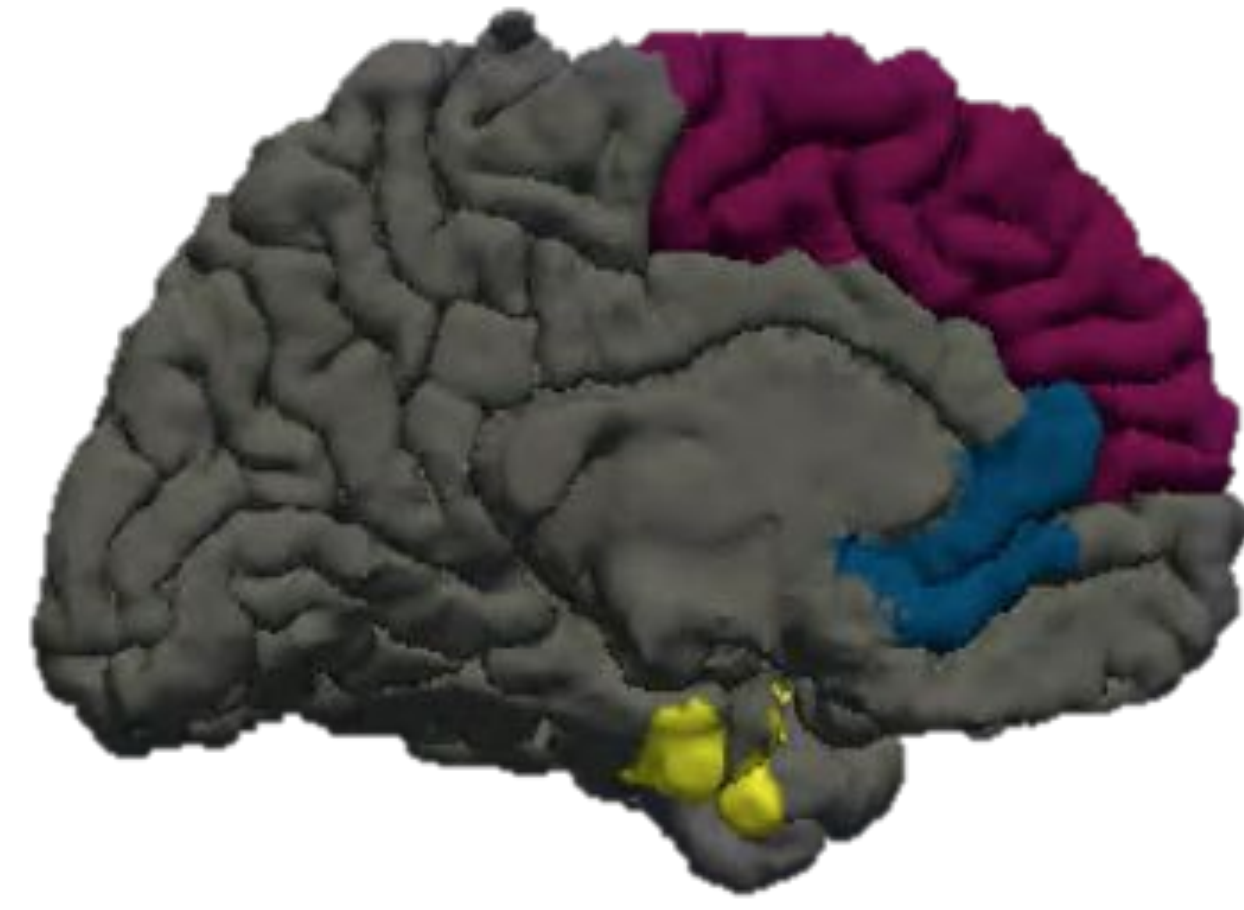
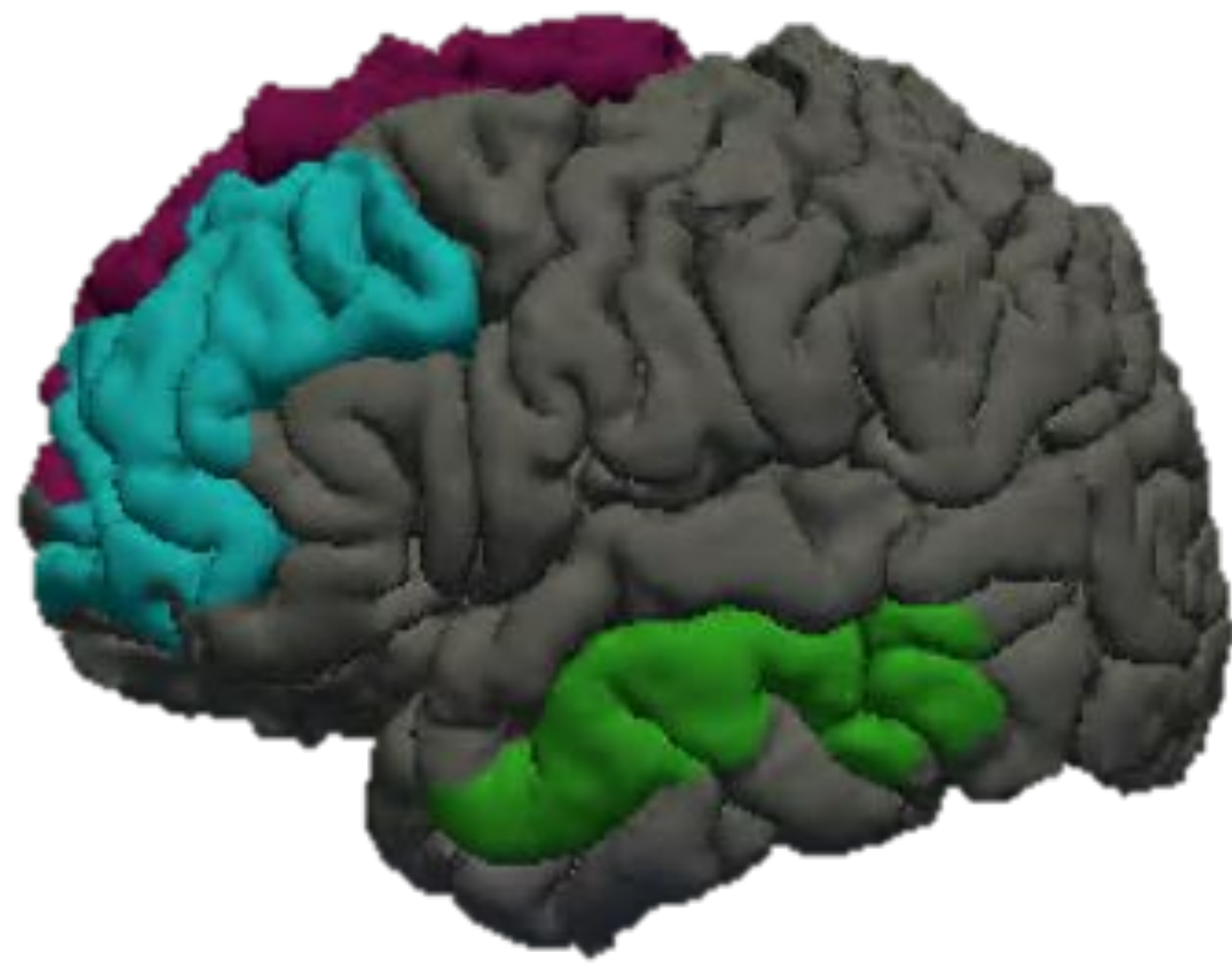
- These results suggest that episodic memory is positively associated with age
- Results also suggest that children with less gray matter in SFC performed better on the memory task
 - This may reflect neural pruning and myelination that occurs during childhood.
- The results show that changes that occur in frontal regions, which are sometimes not thought of as “classical” memory regions, are also important for memory development
- Future research should expand on these findings and study individual differences over time in children to better understand the extent of cortical thinning in various brain regions’ effect on memory

Acknowledgements

We would like to thank the families for participating in the study and the UMD Neurocognitive Development Lab.

References

1. Dickerson, Bradford C, and Howard Eichenbaum. “The Episodic Memory System: Neurocircuitry and Disorders.” *Neuropsychopharmacology*, vol. 35, no. 1, 2009, pp. 86–104., doi:10.1038/npp.2009.126.
2. Fischl, B. (2012). FreeSurfer. *NeuroImage*, 62, 774–781. doi:10.1016/j.neuroimage.2012.01.021.
3. Sur, Mriganka, and Catherine A. Leamey. “Development and Plasticity of Cortical Areas and Networks.” *Nature Reviews Neuroscience*, vol. 2, no. 4, 2001, pp. 251–262., doi:10.1038/35067562.
4. Weintraub, S., Tulskey, D., Dikmen, S., Heaton, R., Fox, N., Havlik, R., . . . Gershon, R. (2008). P2-247: An introduction to the National Institutes of Health (NIH) toolbox for assessment of neurological and behavioral function: Cognition domain. *Alzheimers & Dementia*, 4(4). doi:10.1016/j.jalz.2008.05.1322



Purple = Superior Frontal Cortex
Light blue = Middle Frontal Cortex
Dark blue = Anterior Cingulate Cortex
Green = Middle Temporal Cortex
Yellow = Entorhinal Cortex

